



# Clinical application of the therapeutic ultrasound in urologic disease: Part II of therapeutic ultrasound in urology

Minh-Tung Do<sup>1,2</sup> , Tam Hoai Ly<sup>3</sup> , Min Joo Choi<sup>4,5</sup> , Sung Yong Cho<sup>2,6</sup>

<sup>1</sup>Department of Surgery, Hai Phong University of Medicine and Pharmacy, Hai Phong, Viet Nam, <sup>2</sup>Department of Urology, Seoul National University College of Medicine, Seoul, Korea, <sup>3</sup>Department of Urology, Cho Ray Hospital, Ho Chi Minh City, Viet Nam, <sup>4</sup>Department of Medicine, Jeju National University College of Medicine, Jeju, <sup>5</sup>Interdisciplinary Postgraduate Program in Biomedical Engineering, Jeju National University, Jeju, <sup>6</sup>Department of Urology, Seoul National University Hospital, Seoul, Korea

This article aimed to review the clinical application and evidence of the therapeutic ultrasound in detail for urological diseases such as prostate cancer, kidney tumor, erectile dysfunction, and urolithiasis. We searched for articles about high-intensity focused ultrasound (HIFU), extracorporeal shock wave therapy, ultrasound lithotripsy, and extracorporeal shockwave lithotripsy (ESWL) in the MEDLINE and Embase. HIFU may be indicated as a primary treatment for low- or intermediate-risk prostate cancer, and salvage therapy for local recurrence as a promising way to address the limitations of current standard therapies. The application of HIFU in treating kidney tumors has scarcely been reported with unsatisfactory results. Evidence indicates that low-intensity shockwave therapy improves subjective and objective erectile function in patients with erectile dysfunction. Regarding the application of ultrasound in stone management, the novel combination of ultrasound lithotripsy and other energy sources in a single probe promises to be a game-changer in efficiently disintegrating large kidney stones in percutaneous nephrolithotomy. ESWL is losing its role in managing upper urinary tract calculi worldwide. The burst-wave lithotripsy and ultrasound propulsion could be the new hope to regain its position in the lithotripsy field. According to our investigations and reviews, cavitation bubbles of the therapeutic ultrasound are actively being used in the field of urology. Although clinical evidence has been accumulated in urological diseases such as prostate cancer, kidney tumor, erectile dysfunction, and lithotripsy, further development is needed to be a game-changer in treating these diseases.

**Keywords:** Kidney neoplasms; Prostate; Ultrasonic therapy; Urolithiasis

This is an Open Access article distributed under the terms of the Creative Commons Attribution Non-Commercial License (<http://creativecommons.org/licenses/by-nc/4.0>) which permits unrestricted non-commercial use, distribution, and reproduction in any medium, provided the original work is properly cited.

## INTRODUCTION

In part I of the therapeutic ultrasound in urology, the presenting authors reviewed two types of cavitation bubbles in lithotripsy. Now we would review the clinical application

and evidence of the therapeutic ultrasound in detail for urological diseases such as prostate cancer (PCa), kidney tumor, erectile dysfunction, and urolithiasis in part II of the therapeutic ultrasound.

**Received:** 12 February, 2022 • **Revised:** 14 March, 2022 • **Accepted:** 17 March, 2022 • **Published online:** 16 May, 2022

**Corresponding Author:** Sung Yong Cho <https://orcid.org/0000-0001-9271-6951>

Department of Urology, Seoul National University Hospital, Seoul National University College of Medicine, 101 Daehak-ro, Jongno-gu, Seoul 03080, Korea  
TEL: +82-2-2072-1491, FAX: +82-2-742-4665, E-mail: moretry@snu.ac.kr

## MATERIALS AND METHODS

The presenting authors searched for the articles about high-intensity focused ultrasound (HIFU), extracorporeal shock wave therapy, ultrasound lithotripsy (USL), and extracorporeal shockwave lithotripsy (ESWL) in the major database such as MEDLINE and Embase. We aimed to summarize the updated evidence on the treatment of urological diseases using the therapeutic ultrasound.

## RESULTS

### 1. Physical aspects of high-intensity focused ultrasound in urological cancers

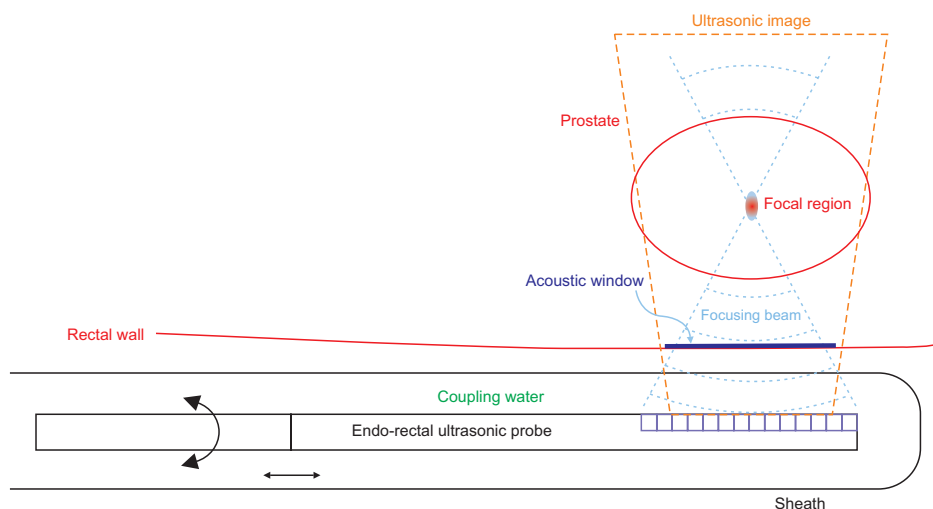
Ultrasound can be tightly focused on a target to produce HIFU. HIFU destroys the tumor target tissue at depths inside the body at a focal point without damaging adjacent tissues or intervening vital structures [1]. This damage is caused by ultrasonic thermal coagulation and destructive mechanical effects, including acoustic cavitation [2]. HIFU devices rely mostly upon ultrasonic heating under continuous or long pulse irradiation [3]. In thermal ablation, the focal intensity needs to be high enough to denature protein and cause coagulative necrosis [4,5]. The latest technology, called “histotripsy,” uses HIFU bursts of higher amplitude but shorter duration to enhance acoustic cavitation [2,6,7]. HIFU appears to be an attractive therapy. This technique is often referred to as “Sonablate ablation,” “ultrasonic ablation,” or “focal ultrasound surgery.”

Imaging modalities are required to accurately locate the target tissues and monitor the surgical process to assure the expected therapeutic outcomes. Ultrasonic imaging is commonly used for continuous monitoring throughout the treatment procedure because it is real-time and has no harmful

effect on the tissues [1]. Ultrasonic methods or X-ray fluoroscopy [2] are limited in monitoring HIFU treatment process since these cannot provide information about temperature rises. Thus, HIFU can be combined with magnetic resonance imaging (MRI) to permit relative thermometry [3]. An MRI-guided HIFU device has proven to better visualize target tissues with temperature changes during the treatment procedure and confirm the surgical efficacy following treatment [4]. However, these are highly costly, and their clinical uses are restricted to a particular application, such as a brain treatment.

A piezoelectric transducer is used as the source of HIFU, which can change its thickness in response to an applied electrical voltage. Focus is achieved by using a transducer [5] or placing a lens in front of a transducer in the case of a single element transducer. Electronic focusing is possible when an array transducer is employed. However, a bone interface interferes with ultrasonic waves, and air or gas layers almost block propagation, obscuring focal targets beyond these interfaces. Accordingly, there are limitations in obtaining an acoustic window in clinical practice, an area on the skin through which ultrasound is transmitted to a target.

Since the transrectal approach easily reaches the prostate gland’s anatomic position, an endorectal ultrasonic transducer can make HIFU irradiation to the prostate [6-8]. An endorectal ultrasonic transducer is inserted into the rectum to deliver HIFU to the prostatic tissue through the rectal wall. An example of such a probe is illustrated in Fig. 1, which consists of many piezoelectric elements linearly arrayed. This probe plays the functional role of both imaging and therapy using electronic beam focusing techniques. The probe is covered with a balloon or a condom filled with air-free acoustic coupling water following insertion into the rectum to get it into close contact with the rectal wall to



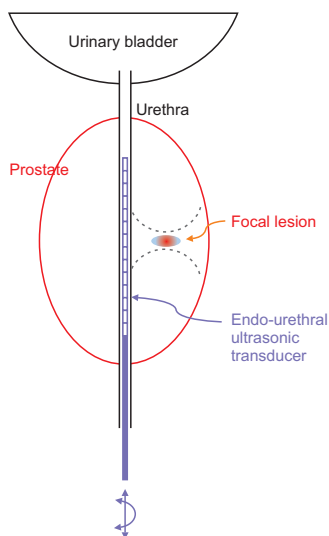
**Fig. 1.** An illustration of an endo-rectal ultrasonic linear array probe, covered by a balloon or a condom filled with air-free acoustic coupling water after insertion into the rectum to get it close contact with the rectal wall for facilitating the ultrasonic transmission to the prostate. The array transducer is designed to play the functional roles of imaging and therapy using electronic beam focusing techniques.

facilitate ultrasonic transmission to the prostate. The probe produces an ellipsoidal or cigar-shaped lesion [9]. The desired volume can be ablated by combining the sequential adjacent focal lesions, which is achieved by moving, translating, or rotating the probe. Care must be taken since HIFU may burn the rectum between the transducer and the prostate [10].

Whereas the transrectal HIFU is used as a minimally invasive treatment for clinically localized PCa in patients not undergoing surgery [6-8,11], a new approach has arisen resulting from the miniaturization of HIFU probes that employ a transurethral HIFU [12]. The prostate tissue is ablated by HIFU delivered from the urethra outwards to the edge of the target region of the prostate (Fig. 2). Being close to the anterior gland, the transurethral HIFU can treat cancers in the anterior portion more effectively. In-bore HIFU with MRI thermometry could help ensure lethal temperatures in the ablation zone and safe temperatures in the urethra and sphincter.

## 2. Clinical aspects of high-intensity focused ultrasound in urologic diseases

HIFU treatments may be efficiently performed with an established procedure. A short learning curve is anticipated with approximately 10 to 15 patients for a skillful urologist in ultrasound prostate imaging.



**Fig. 2.** A schematic illustration of the ablation of the prostate tissue by high-intensity focused ultrasound delivered from the urethra outwards to the edge of the target region of the prostate.

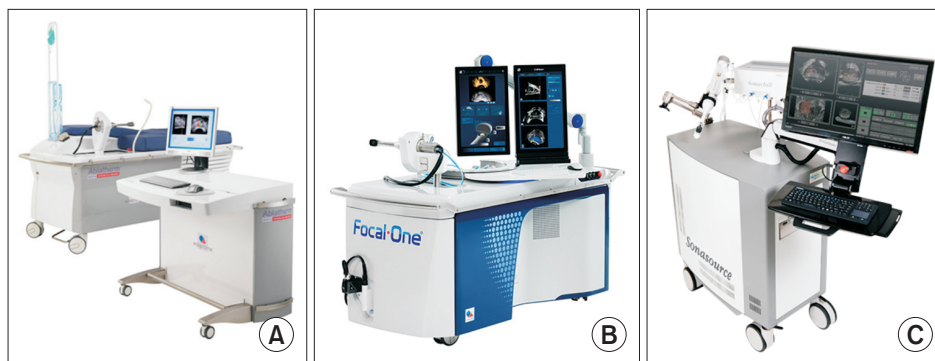
## 1) High-intensity focused ultrasound in urologic cancers

### (1) High-intensity focused ultrasound for treatment of prostate cancer

HIFU has been used to treat PCa for more than 20 years. Though HIFU has not been recommended as a first-line treatment for localized PCa, there are many centers in Europe, Canada, Japan, Korea, Taiwan, and Brazil that have adopted this minimally invasive technique as an alternative to conventional treatment such as radical prostatectomy, external beam radiotherapy, or cryotherapy. To date, mid to long-term results have been reported in thousands of PCa patients, demonstrating that HIFU is a promising way to address the limitations of current standard therapies. In general, HIFU may be indicated as a primary treatment for low- or intermediate-risk PCa and as a salvage therapy for local recurrence following initial treatment.

**Primary treatment of prostate cancer with high-intensity focused ultrasound:** HIFU can be applied as a whole-gland or partial-gland ablation (focal-ablation, hemi-ablation). Whole-gland HIFU was initially considered for men with localized PCa who were not eligible for radical prostatectomy because of comorbidities or did not want to undergo radical prostatectomy [13]. Transurethral prostatectomy or hormone therapy is usually applied prior to HIFU to reduce the prostate volume. The outcomes of whole-gland ablation with HIFU have been reported in many studies. Most patients had low-intermediate risk and baseline prostate-specific antigen (PSA) <10 ng/mL. A small number of high-risk patients was included in several studies [14-20]. The maximum follow-up time was 14 years [19,21]. The 5-year and 10-year overall survival rates were 100% [22] and 88.6% [15], respectively. The PCa-specific and metastasis-free survival rates reached >95% at eight years [8,19] and five years [22], respectively. At eight years, the biochemical disease-free rate was 76% of low-risk patients and 63% of moderate-risk patients [19]. Recurrence rates following whole gland HIFU were associated with cancer grades, PSA levels, prostate volume, and the machine's generation of HIFU [16,19,20]. Although whole-gland HIFU has yielded promising oncological results, morbidity rates remain high. Urinary incontinence, erectile dysfunction, urinary retention, urinary infection, and bladder neck/urethral stenoses rates were 10%, 44%, 11%, 7%, and 15%, respectively [23]. The most severe complication was the urethrorectal fistula, the rate of which was reported to be less than 2%.

The development of cancer localized techniques such as multiparametric MRI and mapping biopsy, the development of HIFU devices (Fig. 3), and the accumulation of clinical experience led to partial HIFU (focal- and hemi-ablation)



**Fig. 3.** Examples of high-intensity focused ultrasound devices. (A) Ablatherm (<http://www.mpuh.org/centreforroboticsurgery/hifu-for-prostate-cancer/>). (B) Focal One (<https://us.hifu-prostate.com/less-invasive-prostate-cancer-treatment-receives-fda-clearance/>). (C) Sonablate (<https://www.innomed.com/urology/sonablate-hifu>).

being used to treat localized PCa. This method is expected to maintain oncologic outcomes and reduce morbidity rates compared to whole-gland ablation. Most studies of partial-gland HIFU ablation included low- and intermediate-risk patients [24-29], but three recent studies have included high-risk patients as well [30-32]. Baseline PSAs were reported to be lower than eight ng/mL, and most studies used multiparametric MRIs and mapping biopsies for tumor localization. The maximum follow-up time was 133 months [31]. The oncologic outcomes of partial-gland ablation HIFU were comparable to the whole-gland ablation method. The overall survival rate was 99% at five years [30] and 97% at eight years [31] in these studies, including high-risk patients. In a study conducted at nine centers in the United Kingdom for more than 10 years, the five-year metastasis-free survival rate was 98%, and PCa specific survival rate was 100%. The biochemical recurrence was 7% to 28% according to Phoenix criteria [29,33] and 8% to 36% according to Stuttgart criteria [29,32]. An increase in the proportion of T2 stage and Gleason score 7 and reduced retreatment rates were observed over time [31]. Partial-gland HIFU ablation for PCa had fewer side effects than whole-gland ablation [25,32,33]. The rates of urinary incontinence, erectile dysfunction, urinary retention, urinary infection, and bladder neck/ urethral stenosis were 2%, 21%, 9%, 11%, and 2%, respectively.

**Salvage treatment of local recurrence prostate cancer with high-intensity focused ultrasound:** HIFU can be used for salvage therapy for locally recurrent PCa following other primary treatments methods. However, only data on HIFU for locally recurrent PCa following external beam radiation therapy, primary HIFU, and radical prostatectomy have been published. A second or third session was done for recurrence in studies of HIFU being used as a primary treatment. The prevalence of second HIFUs ranged from 8% to 38% [15,17,27,34,35]. The second session of HIFU was associated with worse oncologic outcomes and higher rates of urinary incontinence as compared to the primary procedure

but without erectile dysfunction [34].

Sixty-three percent of men experienced disease progression following external beam radiation therapy [36], and local recurrences are treatable with salvage radical prostatectomy. However, the surgical option is associated with a high rate of morbidities [37]. Thus, HIFU has been proposed as an alternative to radical prostatectomy for locally recurrent PCa following external beam radiation therapy. An early report in France showed that 80% of patients had a negative biopsy, and 44% had no disease progression on follow-up [38]. Other French studies of hundreds of prostatectomy patients also showed promising HIFU results for locally recurrent PCa [39,40]. Local cancer control rates were 73% to 80% after HIFU. The five-year overall survival rate reached 84% [39], and seven-year cancer-specific and metastasis-free survival rates were 80% and 79.6%, respectively [40]. The authors suggest high PCa levels before external beam radiation therapy, elevated PSA levels before HIFU, and androgen deprivation therapy during management are associated with higher three-year progression rates following salvage HIFU. Moreover, HIFU shows a better risk/benefit ratio than other types of salvage therapy. Recent studies in Canada [41] and Brazil [42] confirmed that HIFU is a safe and effective option for radiorecurrent PCa.

There are several case series on the efficacy of HIFU as salvage treatment for local PCa recurrence following radical prostatectomy [43,44]. Japanese researchers reported their experiences in using HIFU to treat four cases of local recurrence at the vesicourethral anastomosis following radical prostatectomy. At a 24-month follow-up, two patients were biochemically free, and three were biopsy-free of recurrences without any complications [44]. Another pilot study from Italy on 19 patients found that HIFU was feasible for treating locally recurrent PCa with low morbidity following radical prostatectomy. However, the failure rate remains somewhat high at 52%. This is related to pre-HIFU PSA levels and Gleason scores [43].

## (2) High-intensity focused ultrasound for treatment of kidney tumors

HIFU was expected to substitute for radiofrequency and cryotherapy in treating small renal masses. However, the application of HIFU in treating kidney tumors has scarcely been reported, and the most recent clinical trial of HIFU was conducted about ten years ago [45]. Most studies have shown unsatisfactory results in phase I or phase II clinical trials.

An early study on the feasibility of the extracorporeal HIFU on advanced kidney cancer showed that cancer-related symptoms (hematuria, flank pain) were improved in most cases. However, only 3 of 13 patients achieved complete tumor ablation. Of these 13 patients, six had survived for 18 months [46]. Another clinical phase II of eight renal tumors showed ablation in 4 of 6 (67%) patients assessed by MRI, but only 25% in a case series of 17 patients with a median tumor size of 2.5 cm [47]. The study showed on a follow-up that involution of the ablation zone continued with a mean of 35 months. On follow-up of 14 patients at six months, four had recurrences and had to undergo alternative treatments. An advantage of HIFU is the low complication rate. The most frequent complication is skin toxicities, such as a burn or local edema.

Poor extracorporeal HIFU treatment outcomes for kidney tumors are inherent in the procedure's nature. In addition, it is difficult to obtain a reliable focal point because breathing, the abdominal wall, and the rib cage interfere with the ultrasonic waves. Therefore, a couple of trials were done to make HIFU probe directly contact the tumors via a laparoscopic trocar [45,48]. Although HIFU time was significantly decreased compared with the extracorporeal approach, the outcomes remained unsatisfactory. Moreover, using a laparoscopic approach made HIFU lose its non-invasive nature. Recently, an emerging technology in tumor treatment called boiling histotripsy, which uses HIFU containing shockwaves, could be the future of HIFU in treating renal tumors [49].

## 3. Role of extracorporeal shock wave therapy for erectile dysfunction

As sexual health is an integral part of overall health, erectile dysfunction (ED) can negatively impact the quality of life and men's psychosocial and emotional well-being [50]. Phosphodiesterase type 5 inhibitors (PDE5is) remain the first-line therapy for men with ED because of their efficacy and safety profile. However, there has been a high drop-out rate because of cost, inadequate efficacy, and adverse effects. In addition, their effectiveness decreased in men with

vasculogenic ED (e.g., diabetes, cardiovascular diseases) [51]. Therefore, new treatment modalities that could improve the penile vascular flow are needed.

Shockwave has been used as a non-invasive lithotripsy therapy for years. This is referred to as ESWL. During the development of the ESWL, low-intensity shockwave therapy (LISWT) has developed and been applied to treat several diseases with tissue hypoxia mechanisms, such as chronic wounds [52] and ischemic myocardial disease [53]. LISWT has been investigated for treating ED because of its effects on endothelial dysfunction, a key factor in ED pathogenesis [54]. This causes tissue microtrauma by repetitive shear stress, leading to tissue neovascularization and vasculogenesis via a cascade of regenerative reactions [54,55]. Many studies have demonstrated promising outcomes for treating ED with LISWT. However, the clinical significance of this modality is still questioned.

### 1) Clinical guidelines and recommendations

Current guidelines and recommendations state that the results of LISWT's efficacy are heterogeneous. The American Urological Association 2018 guideline on ED note that "LISWT should be considered investigational [56]." The European Society of Sexual Medicine suggests that LISWT is safe, but its efficacy should be further confirmed [57]. The Asia-Pacific Society for Sexual Medicine supports the application of LISWT in men with ED and suggests that prospective research should focus on specific ED subgroups and optimize protocols [58].

A dozen clinical trials and meta-analyses were performed to evaluate the efficacy and safety of LISWT for ED. The efficacy was assessed by improving the International Index of Erectile Function (IIEF) and erection hardness score (EHS) with baselines, sham procedures, or controls. A meta-analysis of 7 RCTs involving 602 ED patients, average age 60, with an average follow-up of 20 weeks showed that the IIEF improved 6.4 points in LISWT as compared to the baseline versus 1.7 points in the sham procedure groups ( $p < 0.05$ ) [59]. The mean difference (MD) between LISWT and sham treatment was 4.2 points ( $p < 0.001$ ). However, no differences between groups were seen in the meta-regression, controlling for age and baseline IIEF scores. Patients who received a total shock of 18,000 had a higher MD than those who received 6,000 shocks (MD, 7.45 vs. 6.4).

A recent meta-analysis involving 522 vasculogenic ED cases showed that the MD between the IIEF score in the LISWT group and sham group was only 1.2 points at one month and 1.99 points at three to 12 months on follow-up. Interestingly, patients with moderate and severe ED had a

better result than the general population (MD, 3.9). Moreover, in terms of the hardness score, the chance of having a good EHS following treatment was 16 times higher in the LISWT group than in the sham group (OR, 16.2; confidence interval, 7.9–32.3).

Another meta-analysis involving seven randomized controlled trials (RCTs) and seven cohort studies of 833 patients showed that the MD of IIEF was two points higher in the shockwave therapy group than the sham. The severity of ED impacted the outcomes of LISWT, in contrast with the finding in [60]. The lower baseline IIEF is, the smaller MD is. The effect of LISWT was greater in patients taking PDE5i (MD, 4.2) than those without this medication (MD, 1.85). EHS also improved in the LISWT groups compared to the sham group, with the risk difference being 0.47 at one month following treatment and 0.16 at three months. Unfortunately, most studies did not assess LISWT's long-term effect on ED. A short-term follow-up showed that LISWT improved IIEF by 3 to 6 months with an MD of 2.78 compared to baseline [61]. A recently published study that followed up ED patients for more than five years showed that clinical improvements in erectile function decreased 48 to 60 months following completion of LISWT. However, efficacy remained in 40% of patients. LISWT's effect on improving the IIEF score did not differ between PDE5i responders and non-responders. Additionally, the effect was lower in the patients with comorbidities [62]. In penile duplex/triplex ultrasound, LISWT significantly increased penile hemodynamics from baseline [62]. Regarding safety, LISWT is a safe and well-tolerated procedure. No adverse events have been reported related to LISWT or sham procedures. A drop-out rate of 37% in the treatment group and 58% in the sham group has been reported [63].

## 2) Summary of low-intensity shockwave therapy

Taken together, evidence indicates that LISWT improves subjective and objective erectile function in patients with ED regardless of PDE5i response. The treatment effect could increase if associated with PDE5i use and decrease in patients with severe ED or comorbidities. A literature review showed heterogeneity of published data regarding types of machines, settings and treatment protocols, patient selection, and outcomes. Therefore, more large-scale, well-design, long-term follow-up time studies are needed. An optimized set and protocol should be validated as well.

## 4. Role of ultrasound lithotripsy

### 1) Concept of ultrasound lithotripsy

The principle of USL is also based on transforming

electric energy into ultrasonic energy. A generator produces the electricity, and it is transmitted to the transducer with the excitation of a piezoelectric crystal. While the crystal vibrates at a specific frequency, it generates an acoustic wave ranging from 23 to 25 kHz. Mulvaney developed the idea of using ultrasounds in stone fragmentation [64]. The noise level can reach 98 dB [65], imperceptible to the human ears, and the ultrasonic waves are transmitted through the sonotrode to the urinary calculi. During the contact time of the probe, the stone is fragmented with vibration. When the sonotrode contacts the mucosa of the urothelium, the tissue does not resonate with the vibrating energy, and it can minimize tissue damage [66]. The heat damage can also be minimized with an irrigation flow of 30 mL/min because the temperature increase is 1.4°C at most [67]. Therefore, the use of this device can be recommended in percutaneous nephrolithotomy (PCNL) compared to ureteroscopic surgery. The suction power of 60 to 80 cm H<sub>2</sub>O is recommendable to maintain continuous irrigation.

### 2) Role of ultrasound lithotripsy in percutaneous nephrolithotomy

PCNL is the first option for kidney stones >2 [68]. It can break the stone and remove big fragments via a large working channel of the nephroscope. Whereas holmium lasers are increasingly used in mini-PCNL or micro-PCNL, USL is frequently used to disintegrate the stone in standard/conventional PCNL [68]. Probes are available from 2.5 to 6.0 Fr. Many studies have reported the effectiveness of USL in renal stone disintegration compared to other lithotripters. A randomized-control trial that compared the effectiveness of USL and pneumatic lithotripsy (PL) directly in PCNL for renal stone >2 showed that the outcomes did not differ between the two modalities. However, the PL demonstrated a higher stone clearance rate in hard stones, whereas USL could break the soft stones faster than the PL [69]. In another RCT of PCNL for staghorn stones, USL showed comparable efficacy and safety with the use of a high-power holmium laser. But it had a shorter procedure time [70]. The combination of USL and PL in a lithotripter (dual-probe dual-modality) was expected to perform an additive effect, enhancing the efficacy of stone disintegration. Interestingly, the stone-free rate and safety of these combined lithotripters did not outweigh the USL [71-73]. The quest for a better lithotripter for PCNL continues.

Recently, novel single-probe dual-modality lithotripters have been developed and approved. The ShockPulse (Olympus, Tokyo, Japan) utilizes constant ultrasonic energy simultaneously with intermittent ballistic shock wave energy

[74]. The LithoClast Trilogy (EMS, Nyon, Suisse, Switzerland) combines an electromagnetic impactor with ultrasonic energy and suction [75]. The LithoClast Trilogy had the fastest stone clearance time *in vitro*, followed by the ShockPulse, USL only, and combined USL-PL [74]. In a clinical setting, the ShockPulse showed a shorter fragmentation and operative time than the PL in PCNL [76]. However, the stone-free rates and complications were similar. The most recent multicenter prospective study in Europe confirmed its efficacy and safety regarding the lithoclast trilogy. It had not only a high stone clearance rate but also a high stone-free rate [77]. Moreover, effectiveness was observed in both standard PCNL and mini-PCNL [75].

Taken together, USL is still a good option for PCNL. Moreover, the novel combination of USL and other energy sources in a single probe promises to be a game-changer for efficiently disintegrating large kidney stones.

### 3) Role of ultrasound lithotripsy in ureteroscopy

Nowadays, the laser is dominant among lithotripsy methods used in ureteroscopy (URS) with a high stone-free rate and the ability to work with a flexible endoscope. The use of USL in a ureteroscope is less developed than are other lithotriptors because of its bigger diameter. Only a few reports have been published earlier. Most of these studies were conducted in the 1980s and 1990s and used a large ureteroscope (10.5–12.5 Fr) for lithotripsy of distal ureteral stones. The stone-free rate was reported to be more than 90%. In a retrospective study in Brazil in the late 1990s, USL showed a perfect stone-free rate for 1-cm distal ureteral stones, up to 95.6% at the first procedure [78]. The stone-free and fragmentation USL rates were comparable to ureteroscopic electrohydraulic lithotripsy and higher than ESWL but lower than pneumatic modalities in treating ureteral stones [79]. However, the small caliber semi-rigid ureteroscope and small lithotripsy prober demonstrated a higher success rate and fewer complications than did USL [80]. Compared to the working channels of new generation ureteroscopes, the larger size of the probe made USL lose its position in lithotripsy. Despite having a smaller size probe for use with 8 Fr ureteroscopes, in the latest reports of USL in 2004, only 9 of 340 (26%) URS procedures with USL were done in complex ureteral stone cases [81]. Thus, USL seems to have become obsolete in the use of URS. The only advantage that has remained is its unique combination of stone fragmentation and suction. Therefore, it can only be used in a few cases, such as steinstrasse or impacted calcified double J stents [81].

## 5. Extracorporeal shockwave lithotripsy: current and prospective position

ESWL has been used to treat renal and ureteral stones for decades. It was the first-line treatment for uncomplicated upper urinary tract stones smaller than 2 cm [82]. Current guidelines on urolithiasis state that it is still an effective modality for most renal and ureteral stones [83,84]. ESWL can be applied as a first-line treatment for renal stones in both adults and children, combined with PCNL. ESWL is a good treatment option for kidney stones up to 2 cm. The stone-free rate after ESWL for renal stones depends upon its location in the calyceal system. Generally, stone-free rates following ESWL at three months were 65% to 89.2% for upper calyx stones, 64% to 90.5% for middle calyx stones, 63% to 84.4% for lower calyx stones, 67% to 86% for renal pelvis stones, 75.3% to 84.3% for upper ureteral stones, 80.7% to 82.4% for middle ureteral stones, and 76.5% to 91% for lower ureteral stones [85-90]. Stone-free rates in ESWL decrease when the stone burden increases [85,88], the stones are located in the lower calyx, if there are multiple stones, or if there is a history of urolithiasis [91]. The combined use of ESWL and PCNL can improve the stone-free rate in treating complex kidney stones compared with PCNL or ESWL alone [92,93]. Moreover, ESWL is a safe and effective modality to treat urinary stones in children [94].

Although ESWL offers a minor complication rate and reasonable outcomes, there is a worldwide trend away from ESWL toward URS and PCNL for managing upper urinary tract calculi [41,95]. It has several reasons. First, the SWL stone-free rate is lower, and the retreatment rate is higher than URS or PCNL [85,89,95]. Second, the miniaturization of the armamentarium and the navigational changes in PCNL make this a safer procedure than before [96]. The third is the high-speed technical [innovation of flexible ureteroscopes with a small-caliber and clearer view [97]. Last but not least, advances in medical laser technology have made lithotripsy procedures more effective [98].

To regain its position among lithotripsy modalities, several improvements and innovations have been made to optimize the effectiveness of ESWL. First, treatment procedures have been modified to enhance the stone-free rate and reduce renal parenchymal injury [99-101]. Second, optical controls with a camera, which helps to detect and remove the air bubble from the coupling area (called “optical coupling”), reduces the required number of energy shocks [102] and achieves higher stone-free rates than with conventional machines (called “blind coupling”) [103]. Pre-stenting [104] and external vibration/percussion [105,106] are used to accelerate and improve fragment expulsion following ESWL. Third, a

new stone tracking system has been developed to optimize the stone's alignment and focal point and reduce radiation exposure [107]. Additionally, the concept of enlarged focal size with low pressures was suggested to have better stone comminution than conventional narrow focal size lithotripters [108]. However, all the changes mentioned above were based on the traditional shockwave lithotripsy systems, which deliver high-peak pressures in single-cycle pulses at a slow rate [108]. Therefore, the effectiveness of these modifications is still questioned.

Recently, a novel shock wave system has been developed and is expected to be a game-changer in treating urinary calculi. It uses a combination of burst-wave lithotripsy (BWL) and ultrasound propulsion technology [109-111]. BWL delivers a high-frequency, focused sinusoidal acoustic wave in short bursts transcutaneously. In an *in vivo* animal experiment, a lithotripter created a low peak pressure at a high rate on the stone, leading to a finer fragmentation until it achieved a 1-mm size [112] and a smaller than 2-mm size [113]. It also reduced cavitation bubble formation to enhance fragmentation efficiency and minimize tissue injury. No renal parenchymal injury was seen in gross, histologic, or on MRI in the porcine model, although petechial damage and surface erosions were identified on the urothelium around the stone [113]. Seven days following this experiment, there were no significant histological changes to the kidney or surrounding tissue. Serum and urine laboratory tests were normal as well [109]. Thus, BWL could be the potential alternative to the current ESWL generation. The BWL stone clearance could be enhanced with ultrasonic propulsion—a novel stone repositioning technology. Ultrasound propulsion uses a short burst of focused ultrasound pulsed to reposition the stone transcutaneously within the kidney and the ureter. This technology was first introduced in 2010 [114]. Recently, a couple of clinical trials were published [115,116]. The ability of propulsion ultrasound on repositioning the kidney stone was evaluated on patients who had undergone URS for kidney or ureteral stones. Upon visualization with the ureteroscope, the independent observers scored at least one stone's movement (from a collection of dust to 15 mm in size) equal to or greater than 3 mm in 95% of cases. The device was safe and well-tolerated [115]. More recently, the first-in-human study of the BWL system has been published [111]. A 7-mm lower pole kidney stone was broken down into smaller than 2-mm fragments following nine minutes of BWL. These fragments were visualized moving out of the calyx with both an ultrasound and a ureteroscope. The stone free status was confirmed on a 6-week follow-up.

So far, the BWL and ultrasound propulsion could be the

new hope for ESWL to regain its position in the lithotripsy field. Combining these two novel technologies could create an effective office-based system that can break, reposition, and expel urinary stones.

## CONCLUSIONS

According to our investigations and reviews, cavitation bubbles of the therapeutic ultrasound is actively being used in the field of urology. In general, HIFU may be indicated as a primary treatment for low- or intermediate-risk PCa and as a salvage therapy for local recurrence following initial treatment. Though HIFU has not been recommended as a first-line treatment for localized PCa, it was adopted as an alternative to conventional treatment in many centers. The application of HIFU in treating kidney tumors has scarcely been reported on because most studies have shown unsatisfactory results in phase I or phase II clinical trials. LISWT improves erectile function in patients with ED. The treatment effect could increase if associated with PDE5i use and decrease in patients with severe ED or comorbidities. The use of USL device can be recommended in PCNL compared to ureteroscopic surgery and the use of USL for the ureter stones is decreasing. Instead, ESWL has been used to treat renal and ureteral stones for decades. A novel shock wave system of a combination of BWL and ultrasound propulsion technology seems to be a game-changer in treating urinary calculi.

## CONFLICTS OF INTEREST

The authors have nothing to disclose.

## FUNDING

This work was supported by the Korea Medical Device Development Fund grant funded by the Korean government (the Ministry of Science and ICT, the Ministry of Trade, Industry and Energy, the Ministry of Health & Welfare, the Ministry of Food and Drug Safety) (Project Number: KMDF\_PR\_20200901\_0010, 1711134986) (KMDF-RnD, NTIS 202011B04) and, in part, National Research Foundation of Korea (1711145583, 2017R1A2B3007907).

## AUTHORS' CONTRIBUTIONS

Research conception and design: Min Joo Choi and Sung Yong Cho. Data acquisition: Min Joo Choi and Sung Yong Cho. Statistical analysis: Min Joo Choi and Sung Yong Cho.



Data analysis and interpretation: Min Joo Choi and Sung Yong Cho. Drafting of the manuscript: Minh-Tung Do, Tam Hoai Ly, and Sung Yong Cho. Critical revision of the manuscript: Min Joo Choi and Sung Yong Cho. Obtaining funding: Min Joo Choi and Sung Yong Cho. Administrative, technical, or material support: Minh-Tung Do and Tam Hoai Ly. Supervision: Min Joo Choi and Sung Yong Cho. Approval of the final manuscript: all authors.

## REFERENCES

- Luo S, Zhang C, Huang JP, Huang GH, He J. Ultrasound-guided high-intensity focused ultrasound treatment for abdominal wall endometriosis: a retrospective study. *BJOG* 2017;124 Suppl 3:59-63.
- Aginsky R, LeBlang S, Hananel A, Chen J, Gofeld M, Perez J, et al. Tolerability and feasibility of X-ray guided non-invasive ablation of the medial branch nerve with focused ultrasound: preliminary proof of concept in a pre-clinical model. *Ultrasound Med Biol* 2021;47:640-50.
- Giannakou M, Drakos T, Menikou G, Evripidou N, Filippou A, Spanoudes K, et al. Magnetic resonance image-guided focused ultrasound robotic system for transrectal prostate cancer therapy. *Int J Med Robot* 2021;17:e2237.
- Yamauchi FI, Penzkofer T, Fedorov A, Fennessy FM, Chu R, Maier SE, et al. Prostate cancer discrimination in the peripheral zone with a reduced field-of-view T(2)-mapping MRI sequence. *Magn Reson Imaging* 2015;33:525-30.
- ter Haar G. Focused ultrasound therapy. *Curr Opin Urol* 1994;4:89-92.
- Uchida T, Ohkusa H, Yamashita H, Shoji S, Nagata Y, Hyodo T, et al. Five years experience of transrectal high-intensity focused ultrasound using the Sonablate device in the treatment of localized prostate cancer. *Int J Urol* 2006;13:228-33.
- Poissonnier L, Chapelon JY, Rouvière O, Curiel L, Bouvier R, Martin X, et al. Control of prostate cancer by transrectal HIFU in 227 patients. *Eur Urol* 2007;51:381-7.
- Blana A, Murat FJ, Walter B, Thuroff S, Wieland WF, Chaussy C, et al. First analysis of the long-term results with transrectal HIFU in patients with localised prostate cancer. *Eur Urol* 2008;53:1194-201.
- Coleman JA, Scardino PT. Targeted prostate cancer ablation: energy options. *Curr Opin Urol* 2013;23:123-8.
- Nomura T, Mimata H. Focal therapy in the management of prostate cancer: an emerging approach for localized prostate cancer. *Adv Urol* 2012;2012:391437.
- Crouzet S, Murat FJ, Pasticier G, Cassier P, Chapelon JY, Gellet A. High intensity focused ultrasound (HIFU) for prostate cancer: current clinical status, outcomes and future perspectives. *Int J Hyperthermia* 2010;26:796-803.
- Chopra R. Transurethral MR-HIFU for the treatment of localized prostate cancer. *J Ther Ultrasound* 2015;3(Suppl 1):O59.
- Chaussy CG, Thüroff S. High-intensity focused ultrasound for the treatment of prostate cancer: a review. *J Endourol* 2017;31(S1):S30-7.
- Hatiboglu G, Popeneciu IV, Deppert M, Nyarangi-Dix J, Hadaschik B, Hohenfellner M, et al. Quality of life and functional outcome after infravesical desobstruction and HIFU treatment for localized prostate cancer. *BMC Urol* 2017;17:5.
- Uchida T, Tomonaga T, Kim H, Nakano M, Shoji S, Nagata Y, et al. Improved outcomes with advancements in high intensity focused ultrasound devices for the treatment of localized prostate cancer. *J Urol* 2015;193:103-10.
- Pfeiffer D, Berger J, Gross A. Single application of high-intensity focused ultrasound as primary therapy of localized prostate cancer: treatment-related predictors of biochemical outcomes. *Asian J Urol* 2015;2:46-52.
- Mearini L, D'Urso L, Collura D, Nunzi E, Muto G, Porena M. High-intensity focused ultrasound for the treatment of prostate cancer: a prospective trial with long-term follow-up. *Scand J Urol* 2015;49:267-74.
- Bolton D, Ong K, Giles G, Severi G, Lawrentschuk N, Papa N, et al. A whole of population, multiuser series of high-intensity focused ultrasound for management of localized prostate cancer: outcomes and implications. *J Endourol* 2015;29:844-9.
- Crouzet S, Chapelon JY, Rouvière O, Mege-Lechevallier F, Colombel M, Tonoli-Catez H, et al. Whole-gland ablation of localized prostate cancer with high-intensity focused ultrasound: oncologic outcomes and morbidity in 1002 patients. *Eur Urol* 2014;65:907-14.
- Pinthus JH, Farrokhyar F, Hassouna MM, Woods E, Whelan K, Shayegan B, et al. Single-session primary high-intensity focused ultrasonography treatment for localized prostate cancer: biochemical outcomes using third generation-based technology. *BJU Int* 2012;110:1142-8.
- Ganzer R, Fritsche HM, Brandtner A, Bründl J, Koch D, Wieland WF, et al. Fourteen-year oncological and functional outcomes of high-intensity focused ultrasound in localized prostate cancer. *BJU Int* 2013;112:322-9.
- Komura K, Inamoto T, Takai T, Uchimoto T, Saito K, Tanda N, et al. Single session of high-intensity focused ultrasound for localized prostate cancer: treatment outcomes and potential effect as a primary therapy. *World J Urol* 2014;32:1339-45.
- He Y, Tan P, He M, Hu L, Ai J, Yang L, et al. The primary treatment of prostate cancer with high-intensity focused ultrasound: a systematic review and meta-analysis. *Medicine*

- (Baltimore) 2020;99:e22610.
24. Mortezaei A, Krauter J, Gu A, Sonderer J, Bruhin J, Reeve KA, et al. Extensive histological sampling following focal therapy of clinically significant prostate cancer with high intensity focused ultrasound. *J Urol* 2019;202:717-24.
  25. Bass R, Fleshner N, Finelli A, Barkin J, Zhang L, Klotz L. Oncologic and functional outcomes of partial gland ablation with high intensity focused ultrasound for localized prostate cancer. *J Urol* 2019;201:113-9.
  26. Annot A, Olivier J, Valtille P, Deken V, Leroy X, Puech P, et al. Extra-target low-risk prostate cancer: implications for focal high-intensity focused ultrasound of clinically significant prostate cancer. *World J Urol* 2019;37:261-8.
  27. Ganzer R, Hadaschik B, Pahernik S, Koch D, Baumunk D, Kuru T, et al. Prospective multicenter phase II study on focal therapy (hemiblation) of the prostate with high intensity focused ultrasound. *J Urol* 2018;199:983-9.
  28. Rischmann P, Gelet A, Riche B, Villers A, Pasticier G, Bondil P, et al. Focal high intensity focused ultrasound of unilateral localized prostate cancer: a prospective multicentric hemiablation study of 111 patients. *Eur Urol* 2017;71:267-73.
  29. van Velthoven R, Aoun F, Marcelis Q, Albisinni S, Zanaty M, Lemort M, et al. A prospective clinical trial of HIFU hemiablation for clinically localized prostate cancer. *Prostate Cancer Prostatic Dis* 2016;19:79-83.
  30. Guillaumier S, Peters M, Arya M, Afzal N, Charman S, Dudderidge T, et al. A multicentre study of 5-year outcomes following focal therapy in treating clinically significant non-metastatic prostate cancer. *Eur Urol* 2018;74:422-9.
  31. Stabile A, Orczyk C, Hosking-Jervis F, Giganti F, Arya M, Hindley RG, et al. Medium-term oncological outcomes in a large cohort of men treated with either focal or hemi-ablation using high-intensity focused ultrasonography for primary localized prostate cancer. *BJU Int* 2019;124:431-40.
  32. Johnston MJ, Emara A, Noureldin M, Bott S, Hindley RG. Focal high-intensity focussed ultrasound partial gland ablation for the treatment of localised prostate cancer: a report of medium-term outcomes from a single-center in the United Kingdom. *Urology* 2019;133:175-81.
  33. Feijoo ER, Sivaraman A, Barret E, Sanchez-Salas R, Galiano M, Rozet F, et al. Focal high-intensity focused ultrasound targeted hemiablation for unilateral prostate cancer: a prospective evaluation of oncologic and functional outcomes. *Eur Urol* 2016;69:214-20.
  34. Berge V, Dickinson L, McCartan N, Hindley RG, Diep LM, Emberton M, et al. Morbidity associated with primary high intensity focused ultrasound and redo high intensity focused ultrasound for localized prostate cancer. *J Urol* 2014;191:1764-9.
  35. Inoue Y, Goto K, Hayashi T, Hayashi M. Transrectal high-intensity focused ultrasound for treatment of localized prostate cancer. *Int J Urol* 2011;18:358-62.
  36. Agarwal PK, Sadetsky N, Konety BR, Resnick MI, Carroll PR. Treatment failure after primary and salvage therapy for prostate cancer: likelihood, patterns of care, and outcomes. *Cancer* 2008;112:307-14.
  37. Rukstalis DB. Treatment options after failure of radiation therapy—a review. *Rev Urol* 2002;4 Suppl 2:S12-7.
  38. Gelet A, Chapelon JY, Poissonnier L, Bouvier R, Rouvière O, Curiel L, et al. Local recurrence of prostate cancer after external beam radiotherapy: early experience of salvage therapy using high-intensity focused ultrasonography. *Urology* 2004;63:625-9.
  39. Murat FJ, Poissonnier L, Rabilloud M, Belot A, Bouvier R, Rouvière O, et al. Mid-term results demonstrate salvage high-intensity focused ultrasound (HIFU) as an effective and acceptably morbid salvage treatment option for locally radio-recurrent prostate cancer. *Eur Urol* 2009;55:640-7.
  40. Crouzet S, Murat FJ, Pommier P, Poissonnier L, Pasticier G, Rouvière O, et al. Locally recurrent prostate cancer after initial radiation therapy: early salvage high-intensity focused ultrasound improves oncologic outcomes. *Radiother Oncol* 2012;105:198-202.
  41. Geraghty RM, Jones P, Somani BK. Worldwide trends of urinary stone disease treatment over the last two decades: a systematic review. *J Endourol* 2017;31:547-56.
  42. Dason S, Wong NC, Allard CB, Hoogenes J, Orovan W, Shayegan B. High-intensity Focused Ultrasound (HIFU) as salvage therapy for radio-recurrent prostate cancer: predictors of disease response. *Int Braz J Urol* 2018;44:248-57.
  43. Asimakopoulos AD, Miano R, Virgili G, Vespasiani G, Finazzi Agrò E. HIFU as salvage first-line treatment for palpable, TRUS-evidenced, biopsy-proven locally recurrent prostate cancer after radical prostatectomy: a pilot study. *Urol Oncol* 2012;30:577-83.
  44. Murota-Kawano A, Nakano M, Hongo S, Shoji S, Nagata Y, Uchida T. Salvage high-intensity focused ultrasound for biopsy-confirmed local recurrence of prostate cancer after radical prostatectomy. *BJU Int* 2010;105:1642-5.
  45. Ritchie RW, Leslie TA, Turner GD, Roberts IS, D'Urso L, Coltura D, et al. Laparoscopic high-intensity focused ultrasound for renal tumours: a proof of concept study. *BJU Int* 2011;107:1290-6.
  46. Wu F, Wang ZB, Chen WZ, Bai J, Zhu H, Qiao TY. Preliminary experience using high intensity focused ultrasound for the treatment of patients with advanced stage renal malignancy. *J Urol* 2003;170(6 Pt 1):2237-40.
  47. Ritchie RW, Leslie T, Phillips R, Wu F, Illing R, ter Haar G, et

- al. Extracorporeal high intensity focused ultrasound for renal tumours: a 3-year follow-up. *BJU Int* 2010;106:1004-9.
48. Klingler HC, Susani M, Seip R, Mauermann J, Sanghvi N, Marberger MJ. A novel approach to energy ablative therapy of small renal tumours: laparoscopic high-intensity focused ultrasound. *Eur Urol* 2008;53:810-6; discussion 817-8.
  49. Khokhlova TD, Schade GR, Wang YN, Buravkov SV, Chernikov VP, Simon JC, et al. Pilot in vivo studies on transcutaneous boiling histotripsy in porcine liver and kidney. *Sci Rep* 2019;9:20176.
  50. Montorsi F, Adaikan G, Becher E, Giuliano F, Khoury S, Lue TF, et al. Summary of the recommendations on sexual dysfunctions in men. *J Sex Med* 2010;7:3572-88.
  51. Hatzimouratidis K, Salonia A, Adaikan G, Buvat J, Carrier S, El-Meliegy A, et al. Pharmacotherapy for erectile dysfunction: recommendations from the Fourth International Consultation for Sexual Medicine (ICSM 2015). *J Sex Med* 2016;13:465-88.
  52. Hayashi D, Kawakami K, Ito K, Ishii K, Tanno H, Imai Y, et al. Low-energy extracorporeal shock wave therapy enhances skin wound healing in diabetic mice: a critical role of endothelial nitric oxide synthase. *Wound Repair Regen* 2012;20:887-95.
  53. Becker M, Goetzenich A, Roehl AB, Huebel C, de la Fuente M, Dietz-Laursonn K, et al. Myocardial effects of local shock wave therapy in a Langendorff model. *Ultrasonics* 2014;54:131-6.
  54. d'Agostino MC, Craig K, Tibalt E, Respizzi S. Shock wave as biological therapeutic tool: from mechanical stimulation to recovery and healing, through mechanotransduction. *Int J Surg* 2015;24(Pt B):147-53.
  55. Sukubo NG, Tibalt E, Respizzi S, Locati M, d'Agostino MC. Effect of shock waves on macrophages: a possible role in tissue regeneration and remodeling. *Int J Surg* 2015;24(Pt B):124-30.
  56. Burnett AL, Nehra A, Breau RH, Culkin DJ, Faraday MM, Hakim LS, et al. Erectile dysfunction: AUA guideline. *J Urol* 2018;200:633-41. Erratum in: *J Urol* 2022;207:743.
  57. Capogrosso P, Frey A, Jensen CFS, Rastrelli G, Russo GI, Torremade J, et al. Low-intensity shock wave therapy in sexual medicine-clinical recommendations from the European Society of Sexual Medicine (ESSM). *J Sex Med* 2019;16:1490-505.
  58. Chung E, Lee J, Liu CC, Taniguchi H, Zhou HL, Park HJ. Clinical practice guideline recommendation on the use of low intensity extracorporeal shock wave therapy and low intensity pulsed ultrasound shock wave therapy to treat erectile dysfunction: the Asia-Pacific Society for Sexual Medicine position statement. *World J Mens Health* 2021;39:1-8.
  59. Clavijo RI, Kohn TP, Kohn JR, Ramasamy R. Effects of low-intensity extracorporeal shockwave therapy on erectile dysfunction: a systematic review and meta-analysis. *J Sex Med* 2017;14:27-35.
  60. Dong L, Chang D, Zhang X, Li J, Yang F, Tan K, et al. Effect of low-intensity extracorporeal shock wave on the treatment of erectile dysfunction: a systematic review and meta-analysis. *Am J Mens Health* 2019;13:1557988319846749.
  61. Angulo JC, Arance I, de Las Heras MM, Meilán E, Esquinas C, Andrés EM. Efficacy of low-intensity shock wave therapy for erectile dysfunction: a systematic review and meta-analysis. *Actas Urol Esp* 2017;41:479-90.
  62. Sokolakis I, Hatzichristodoulou G. Clinical studies on low intensity extracorporeal shockwave therapy for erectile dysfunction: a systematic review and meta-analysis of randomised controlled trials. *Int J Impot Res* 2019;31:177-94.
  63. Srini VS, Reddy RK, Shultz T, Denes B. Low intensity extracorporeal shockwave therapy for erectile dysfunction: a study in an Indian population. *Can J Urol* 2015;22:7614-22.
  64. Mulvaney WP. Attempted disintegration of calculi by ultrasonic vibrations. *J Urol* 1953;70:704-7.
  65. LeRoy AJ, May GR, Bender CE, Williams HJ Jr, McGough PF, Segura JW, et al. Percutaneous nephrostomy for stone removal. *Radiology* 1984;151:607-12.
  66. Grocela JA, Dretler SP. Intracorporeal lithotripsy. Instrumentation and development. *Urol Clin North Am* 1997;24:13-23.
  67. Marberger M. Disintegration of renal and ureteral calculi with ultrasound. *Urol Clin North Am* 1983;10:729-42.
  68. EAU guidelines on urolithiasis 2022 [Internet]. Arnhem: European Association of Urology; 2022. Available from: <https://uroweb.org/guidelines/urolithiasis>.
  69. Radfar MH, Basiri A, Nouralizadeh A, Shemshaki H, Sarhangnejad R, Kashi AH, et al. Comparing the efficacy and safety of ultrasonic versus pneumatic lithotripsy in percutaneous nephrolithotomy: a randomized clinical trial. *Eur Urol Focus* 2017;3:82-8.
  70. EL-Nahas AR, Elshal AM, EL-Tabey NA, EL-Assmy AM, Shokeir AA. Percutaneous nephrolithotomy for staghorn stones: a randomised trial comparing high-power holmium laser versus ultrasonic lithotripsy. *BJU Int* 2016;118:307-12.
  71. Zengin K, Sener NC, Bas O, Nalbant I, Alisir I. Comparison of pneumatic, ultrasonic and combination lithotripters in percutaneous nephrolithotripsy. *Int Braz J Urol* 2014;40:650-5.
  72. Karakan T, Diri A, Hascicek AM, Ozgur BC, Ozcan S, Eroglu M. Comparison of ultrasonic and pneumatic intracorporeal lithotripsy techniques during percutaneous nephrolithotomy. *ScientificWorldJournal* 2013;2013:604361.
  73. Lehman DS, Hrubby GW, Phillips C, Venkatesh R, Best S, Monga M, et al. Prospective randomized comparison of a

- combined ultrasonic and pneumatic lithotrite with a standard ultrasonic lithotrite for percutaneous nephrolithotomy. *J Endourol* 2008;22:285-9.
74. Carlos EC, Wollin DA, Winship BB, Jiang R, Radvak D, Chew BH, et al. In vitro comparison of a novel single probe dual-energy lithotripter to current devices. *J Endourol* 2018;32:534-40.
  75. Sabnis RB, Balaji SS, Sonawane PL, Sharma R, Vijayakumar M, Singh AG, et al. EMS Lithoclast Trilogy™: an effective single-probe dual-energy lithotripter for mini and standard PCNL. *World J Urol* 2020;38:1043-50.
  76. Yadav BK, Basnet RB, Shrestha A, Shrestha PM. Comparison between shockpulse and pneumatic lithotripsy in percutaneous nephrolithotomy. *World J Urol* 2021;39:915-9.
  77. Thakare N, Tanase F, Saeb-Parsy K, Atassi N, Endriss R, Kamphuis G, et al. Efficacy and safety of the EMS Swiss LithoClast® Trilogy for PCNL: results of the European multicentre prospective study on behalf of European Section of UroTechnology. *World J Urol* 2021;39:4247-53.
  78. Netto Júnior NR, Claro Jde A, Esteves SC, Andrade EF. Ureteroscopic stone removal in the distal ureter. Why change? *J Urol* 1997;157:2081-3.
  79. Küpeli B, Biri H, Isen K, Onaran M, Alkibay T, Karaođlan U, et al. Treatment of ureteral stones: comparison of extracorporeal shock wave lithotripsy and endourologic alternatives. *Eur Urol* 1998;34:474-9.
  80. Murthy PV, Rao HS, Meherwade S, Rao PV, Srivastava A, Sasidharan K. Ureteroscopic lithotripsy using mini-endoscope and Swiss lithoclast: experience in 147 cases. *J Endourol* 1997;11:327-30.
  81. Gur U, Lifshitz DA, Lask D, Livne PM. Ureteral ultrasonic lithotripsy revisited: a neglected tool? *J Endourol* 2004;18:137-40.
  82. Preminger GM, Tiselius HG, Assimos DG, Alken P, Buck C, Gallucci M, et al. 2007 guideline for the management of ureteral calculi. *J Urol* 2007;178:2418-34.
  83. Türk C, Petřík A, Sarica K, Seitz C, Skolarikos A, Straub M, et al. EAU guidelines on interventional treatment for urolithiasis. *Eur Urol* 2016;69:475-82.
  84. Taguchi K, Cho SY, Ng AC, Usawachintachit M, Tan YK, Deng YL, et al. The Urological Association of Asia clinical guideline for urinary stone disease. *Int J Urol* 2019;26:688-709.
  85. Chung VY, Turney BW. The success of shock wave lithotripsy (SWL) in treating moderate-sized (10-20 mm) renal stones. *Urolithiasis* 2016;44:441-4.
  86. White W, Klein F. Five-year clinical experience with the Dornier Delta lithotripter. *Urology* 2006;68:28-32.
  87. Zehnder P, Roth B, Birkhäuser F, Schneider S, Schmutz R, Thalmann GN, et al. A prospective randomised trial comparing the modified HM3 with the MODULITH® SLX-F2 lithotripter. *Eur Urol* 2011;59:637-44.
  88. Obek C, Onal B, Kantay K, Kalkan M, Yałçın V, Oner A, et al. The efficacy of extracorporeal shock wave lithotripsy for isolated lower pole calculi compared with isolated middle and upper caliceal calculi. *J Urol* 2001;166:2081-4; discussion 2085.
  89. Bas O, Bakirtas H, Sener NC, Ozturk U, Tuygun C, Goktug HN, et al. Comparison of shock wave lithotripsy, flexible ureterorenoscopy and percutaneous nephrolithotripsy on moderate size renal pelvis stones. *Urolithiasis* 2014;42:115-20.
  90. Coz F, Orvieto M, Bustos M, Lyng R, Stein C, Hinrichs A, et al. Extracorporeal shockwave lithotripsy of 2000 urinary calculi with the modulith SL-20: success and failure according to size and location of stones. *J Endourol* 2000;14:239-46.
  91. Abe T, Akakura K, Kawaguchi M, Ueda T, Ichikawa T, Ito H, et al. Outcomes of shockwave lithotripsy for upper urinary-tract stones: a large-scale study at a single institution. *J Endourol* 2005;19:768-73.
  92. He XZ, Ou TW, Cui X, Li J, Wang SH. Analysis of the safety and efficacy of combined extracorporeal shock wave lithotripsy and percutaneous nephrolithotomy for the treatment of complex renal calculus. *Eur Rev Med Pharmacol Sci* 2017;21:2567-71.
  93. Meretyk S, Gofrit ON, Gafni O, Pode D, Shapiro A, Verstandig A, et al. Complete staghorn calculi: random prospective comparison between extracorporeal shock wave lithotripsy monotherapy and combined with percutaneous nephrostolithotomy. *J Urol* 1997;157:780-6.
  94. Badawy AA, Saleem MD, Abolyosr A, Aldahshoury M, Elbadry MS, Abdalla MA, et al. Extracorporeal shock wave lithotripsy as first line treatment for urinary tract stones in children: outcome of 500 cases. *Int Urol Nephrol* 2012;44:661-6.
  95. Srisubata A, Potisat S, Lojanapiwat B, Setthawong V, Lao-paiboon M. Extracorporeal shock wave lithotripsy (ESWL) versus percutaneous nephrolithotomy (PCNL) or retrograde intrarenal surgery (RIRS) for kidney stones. *Cochrane Database Syst Rev* 2014;(11):CD007044.
  96. Rassweiler J, Rassweiler MC, Klein J. New technology in ureteroscopy and percutaneous nephrolithotomy. *Curr Opin Urol* 2016;26:95-106.
  97. Sanguedolce F, Bozzini G, Chew B, Kallidonis P, de la Rosette J. The evolving role of retrograde intrarenal surgery in the treatment of urolithiasis. *Eur Urol Focus* 2017;3:46-55.
  98. Kronenberg P, Somani B. Advances in lasers for the treatment of stones-a systematic review. *Curr Urol Rep* 2018;19:45.
  99. Nguyen DP, Hnilicka S, Kiss B, Seiler R, Thalmann GN, Roth B. Optimization of extracorporeal shock wave lithotripsy

- delivery rates achieves excellent outcomes for ureteral stones: results of a prospective randomized trial. *J Urol* 2015;194:418-23.
100. Skuginna V, Nguyen DP, Seiler R, Kiss B, Thalmann GN, Roth B. Does stepwise voltage ramping protect the kidney from injury during extracorporeal shockwave lithotripsy? Results of a prospective randomized trial. *Eur Urol* 2016;69:267-73.
  101. López-Acón JD, Budía Alba A, Bahílo-Mateu P, Trassierra-Villa M, de los Ángeles Conca-Baenas M, de Guzmán Ordaz-Jurado D, et al. Analysis of the efficacy and safety of increasing the energy dose applied per session by increasing the number of shock waves in extracorporeal lithotripsy: a prospective and comparative study. *J Endourol* 2017;31:1289-94.
  102. Taily GG, Taily-Cusse MM. Optical coupling control: an important step toward better shockwave lithotripsy. *J Endourol* 2014;28:1368-73.
  103. Lv JL. A new optical coupling control technique and application in SWL. *Urolithiasis* 2016;44:539-44.
  104. Sharma R, Choudhary A, Das RK, Basu S, Dey RK, Gupta R, et al. Can a brief period of double J stenting improve the outcome of extracorporeal shock wave lithotripsy for renal calculi sized 1 to 2 cm? *Investig Clin Urol* 2017;58:103-8.
  105. Wu W, Yang Z, Tang F, Xu C, Wang Y, Gu X, et al. How to accelerate the upper urinary stone discharge after extracorporeal shockwave lithotripsy (ESWL) for < 15 mm upper urinary stones: a prospective multi-center randomized controlled trial about external physical vibration lithotripsy (EPVL). *World J Urol* 2018;36:293-8.
  106. Jing S, Liu B, Lan W, Zhao X, Bao J, Ma J, et al. Modified mechanical percussion for upper urinary tract stone fragments after extracorporeal shock wave lithotripsy: a prospective multicenter randomized controlled trial. *Urology* 2018;116:47-54.
  107. Abid N, Ravier E, Promeprat X, Coudas R, Fehri HF, Crouzet S, et al. Decreased radiation exposure and increased efficacy in extracorporeal lithotripsy using a new ultrasound stone locking system. *J Endourol* 2015;29:1263-9.
  108. Xing Y, Chen TT, Simmons WN, Sankin G, Cocks FH, Lipkin ME, et al. Comparison of broad vs narrow focal width lithotripter fields. *J Endourol* 2017;31:502-9.
  109. Bailey MR, Wang YN, Kreider W, Dai JC, Cunitz BW, Harper JD, et al. Update on clinical trials of kidney stone repositioning and preclinical results of stone breaking with one system. *Proc Meet Acoust* 2018;35:020004.
  110. Chen TT, Samson PC, Sorensen MD, Bailey MR. Burst wave lithotripsy and acoustic manipulation of stones. *Curr Opin Urol* 2020;30:149-56.
  111. Harper JD, Metzler I, Hall MK, Chen TT, Maxwell AD, Cunitz BW, et al. First in-human burst wave lithotripsy for kidney stone comminution: initial two case studies. *J Endourol* 2021;35:506-11.
  112. Maxwell AD, Cunitz BW, Kreider W, Sapozhnikov OA, Hsi RS, Harper JD, et al. Fragmentation of urinary calculi in vitro by burst wave lithotripsy. *J Urol* 2015;193:338-44.
  113. Maxwell AD, Wang YN, Kreider W, Cunitz BW, Starr F, Lee D, et al. Evaluation of renal stone comminution and injury by burst wave lithotripsy in a pig model. *J Endourol* 2019;33:787-92.
  114. Shah A, Owen NR, Lu W, Cunitz BW, Kaczowski PJ, Harper JD, et al. Novel ultrasound method to reposition kidney stones. *Urol Res* 2010;38:491-5.
  115. Dai JC, Sorensen MD, Chang HC, Samson PC, Dunmire B, Cunitz BW, et al. Quantitative assessment of effectiveness of ultrasonic propulsion of kidney stones. *J Endourol* 2019;33:850-7.
  116. Harper JD, Cunitz BW, Dunmire B, Lee FC, Sorensen MD, Hsi RS, et al. First in human clinical trial of ultrasonic propulsion of kidney stones. *J Urol* 2016;195(4 Pt 1):956-64.